

**To cite this article:**

Iwona Wysoczańska-Jankowicz, Tomasz Stefański, Agnieszka Waclawczyk, et al.: Apexification of permanent immature teeth using MTA – a report of cases. Apeksyfikacja zębów stałych niedojrzałych z użyciem MTA – opis przypadków. Nowa Stomatol 2022;27(2):65-74.  
DOI: 10.25121/NS.2022.27.2.65

**To link to this article:**

<https://doi.org/10.25121/NS.2022.27.2.65>

IWONA WYSOCZAŃSKA-JANKOWICZ<sup>1</sup>, TOMASZ STEFAŃSKI<sup>2</sup>, AGNIESZKA WACLAWCZYK<sup>1</sup>, JACEK BEDNARSKI<sup>3</sup>,  
\*LIDIA POSTEK-STEFAŃSKA<sup>1</sup>

## Apexification of permanent immature teeth using MTA – a report of cases

Apeksyfikacja zębów stałych niedojrzałych z użyciem MTA – opis przypadków

<sup>1</sup>Department of Pediatric Dentistry, Faculty of Medical Sciences in Zabrze, Medical University of Silesia in Katowice  
Head of Department: Lidia Postek-Stefańska, MD, PhD SUM

<sup>2</sup>Department of Orthodontics, Faculty of Medical Sciences in Zabrze, Medical University of Silesia in Katowice  
Head of Department: Agnieszka Machorowska-Pieniążek, MD

<sup>3</sup>Dębowa 105 Stomatologia i Medycyna Estetyczna Sp. z o.o., Katowice

**KEYWORDS**

apexification, pulp necrosis, immature permanent teeth, root canal treatment, MTA

**SUMMARY**

Immature permanent teeth with necrotic pulp require endodontic treatment different than conventional procedure. Proper root canal treatment and correct filling of such teeth is hardly possible due to open wide apices. Apexification is a method that enables to create hard apical barrier. Until recently the most common material in this method was calcium hydroxide. It is highly effective, however using calcium hydroxide requires long time treatment up to 24 months with many appointments to create mineral apical barrier. This may lead to fracture of the root's thin walls end tooth extraction. Currently, the MTA (Mineral Trioxide Aggregate) preparation is recommended in the apexification procedure to close open apex of immature teeth. It enables to carry out apexification procedure during one or two appointments.

The aim of this study is to describe 5 cases of apexification in posttraumatic and due to caries non-vital immature teeth using MTA. In the following period of observation in all the presented cases a positive treatment result was obtained.

In all the presented cases a positive treatment result was obtained.

**SŁOWA KLUCZOWE**

apeksyfikacja, martwica miazgi, niedojrzałe zęby stałe, leczenie kanałowe, MTA

**STRESZCZENIE**

Niedojrzałe zęby stałe z martwą miazgą wymagają leczenia endodontycznego, które różni się od stosowanego w zębach dojrzałych. Prawidłowe leczenie kanałów korzeniowych w zębach niedojrzałych i właściwe ich wypełnienie nastręcza wielu trudności z powodu szerokiego otworu wierzchołkowego. Apeksyfikacja umożliwia tworzenie twardej bariery wierzchołkowej. Do niedawna najczęściej używanym materiałem w tej metodzie był wo-

dorotlenek wapnia. Jest on bardzo efektywny, jednak wymaga wieloetapowego, długiego postępowania, do 24 miesięcy, w celu utworzenia zmineralizowanej bariery wierzchołkowej. Może to przyczynić się do złamania cienkich ścian korzeniowych i ekstrakcji zęba. Aktualnie do zamykania otworów wierzchołkowych w niedojrzałych zębach stałych rekomendowany jest materiał MTA, który umożliwia przeprowadzenie apeksyfikacji na jednej lub dwóch wizytach.

Celem niniejszej pracy jest przedstawienie 5 przypadków zębów stałych niedojrzałych z pourazową lub w przebiegu próchnicy martwicą miążgi, w których w leczeniu apeksyfikacyjnym zastosowano MTA.

We wszystkich przypadkach uzyskano pozytywne wyniki leczenia.

## INTRODUCTION

Teeth with necrotic pulp or irreversible pulpitis require root canal treatment. The outcome of endodontic treatment depends on various factors such as: diagnosis, correct instrumentation, disinfection and tight seal obturation of the root canal system. These procedures are routinely performed in fully developed teeth. An optimal filling of the root canal system of non-vital immature teeth with open apices is always problematic for dental practitioners (1, 2). The immature teeth have incomplete root development. Root walls are thin and divergent and the apical foramen is wide opened, therefore it is impossible to seal the root canal with traditional obturation methods (2).

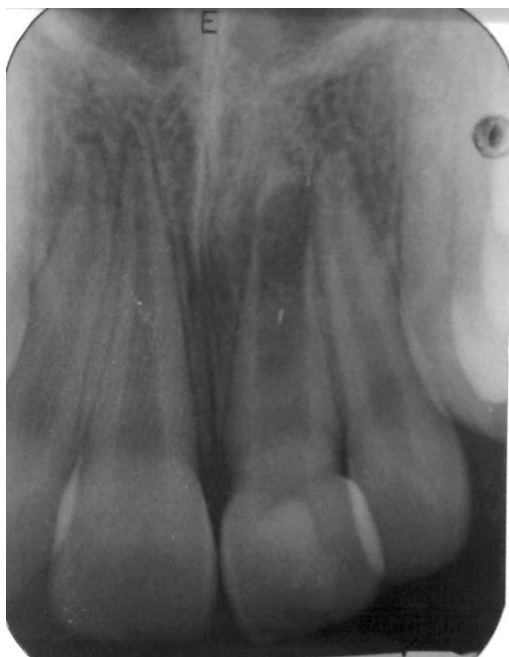Apexification is root canal treatment in immature permanent teeth in which root formation ceased due to pulpal necrosis or irreversible pulpitis. The purpose of this procedure is to removal of necrotic pulp, debridement of the canal, control of infection and induce root end closure by forming a barrier to facilitate obturation of the canal (2, 3). There are generally two ways to reach this goal. First one is based on multiple visits when the internal dressing of the root is changed in 3-6 months periods. Calcium hydroxide is the most common preparation used for this purpose (2, 3), since its antimicrobial and odontotropic action limits bacterial infection and enables the formation of a natural calcified apical barrier. However, calcium hydroxide has some relevant disadvantages, including high solubility and low mechanical stability, which may pose risk of fracture to the thin root walls (3-6). Moreover, the average time for apical barrier formation ranges from 5 to 24 months necessitating multiple-visit treatment, during which a leakage around provisional restoration may result in bacterial re-contamination of the root canal system (2, 6-8). As all these factors may lead to the failure, other materials have also been used as a root-end filling in the apexification procedure. One of them is MTA (Mineral Trioxide Aggregate), which consists of hydrophilic particles of calcium, magnesium, silicone, ferrous oxides that in wet conditions create colloidal gel. Material sets to a hard structure in about 3 hours after application and its compressive strength are similar to that of IRM® (Immediate Restorative Material) or super-EBA® (Ethoxy Benzoic Acid) cements (7). One of the main reasons for using MTA as root canal filling material in apexification is its biocompatibility, osteogenic properties, great sealing ability and marginal adaptation. MTA is considered as

a bacteriostatic and bactericidal material due to release of hydroxyl ions during setting and maintaining high pH. Formation of mineralized layer between MTA and dentin as well as the fact that MTA can penetrate dentinal tubules provide challenging conditions for bacterial survival including *Enterococcus faecalis* and *Candida albicans* that are often cause of unsuccessful endodontic treatment. What is more, setting properties of MTA are not susceptible to moisture and bleeding. MTA in contrast to calcium hydroxide does not undergo disintegration in time (8-11).

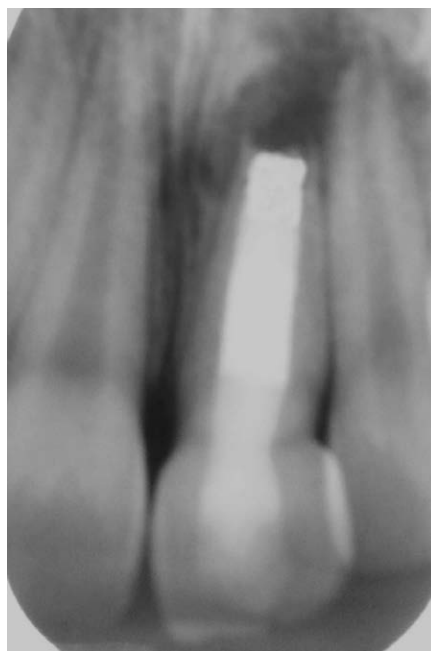
During apexification procedure MTA is placed at the apical part of the root. This enables to create an artificial hard apical barrier, also known as "apical stop" or "apical plug", on a single visit and reduces risk factors connected with using calcium hydroxide. Before next appointment the material is hardened and the apical closure is achieved. Then, the backfill part of the obturation using gutta-percha may be carried out.

## REPORT OF CASES

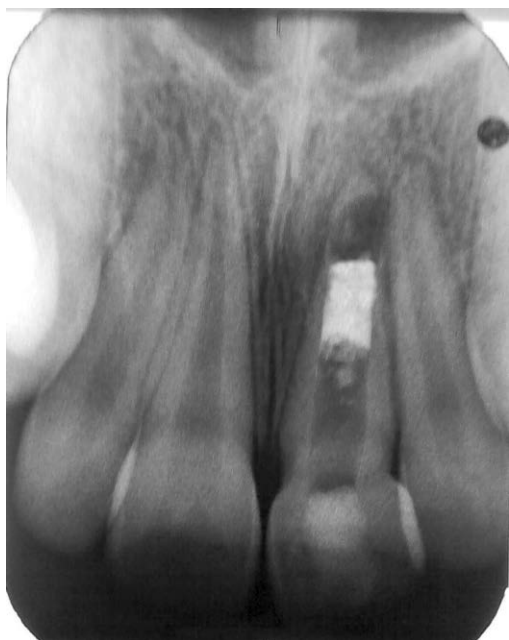Apexification with the use of MTA was carried out in 5 patients: in 4 patients in central maxillary incisors due to traumatic injuries and in 1 patient in mandibular premolar due to caries. The clinical examination showed that treated teeth were non vital and the radiographs revealed incomplete root development. All procedures were completed under dental operating microscope after obtaining an informed consent from the parents. Patients were locally anesthetized with articaine with 1:200 000 epinephrine. Instrumentation of root canal with crown-down technique was made after placing a rubber dam and the radiographic working length determination. Preparation of the root canal was mainly physical chemical due to their thin walls. The canals were irrigated with 2% sodium hypochlorite and 0.9% saline solution. Calibrated paper points were used to dry the canals. A portion of absorbable collagen sponge (Biokol, Stalmed Kielce or Spongostan, Ferrosan) was placed at the root end to allow MTA to be placed within the confines of the canal large space to prevent its extrusion (12, 13). In four teeth ProRoot MTA (Dentsply Maillefer, Tulsa, OK, USA) was applied with a special carrier and then condensed in the apex using Gutta-Condensers and paper points. The final apical plug thickness was 3-4 mm. Subsequently, the wet cotton pellet was placed in the pulp chamber and the cavity was closed with glass ionomer. In one case fast setting Bio MTA



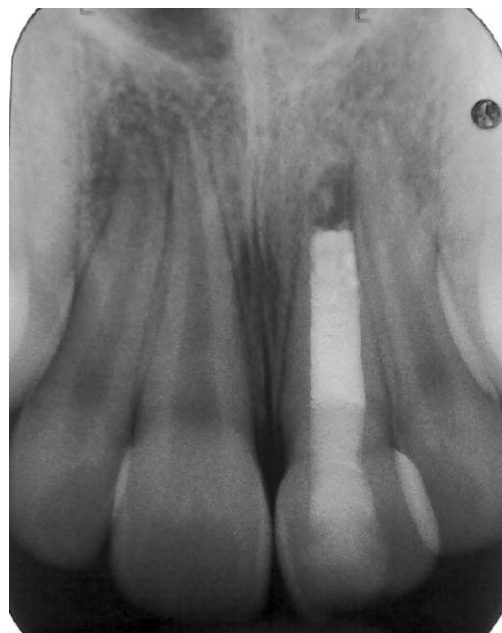**Fig. 1a.** Immature tooth 21 with necrotic pulp and periapical lesion in 10-years old patient



**Fig. 1c.** Tooth 21 after backfill obturation



**Fig. 1b.** Tooth 21 after placement of MTA apical plug



**Fig. 1d.** Follow-up of tooth 21 after 12 months

(Cerkamed, Stalowa Wola, Poland) was used in the apexification procedure (12, 13). The X-ray was taken to confirm the correct position of the apical plug. In four teeth with MTA on the next appointment the temporary filling was removed and the canal was backfilled using Obtura (Spartan) with thermoplastic gutta-percha with AH Plus Sealer (Dentsply De Trey) and the crown was finally restored with a composite material. In one tooth in which Bio MTA was used the canal was backfilled with Obtura System on the

same visit. Another X-ray was taken in the end of the treatment. An amoxicilline was prescribed in all cases. The patients attended recall appointments, after 6, 12 months or longer period – 30 and 36 months, during which a control radiographic examination was performed.

#### Case 1

A 10-year-old boy with Class II malocclusion suffered trauma to the upper central left incisor 1.5 years before

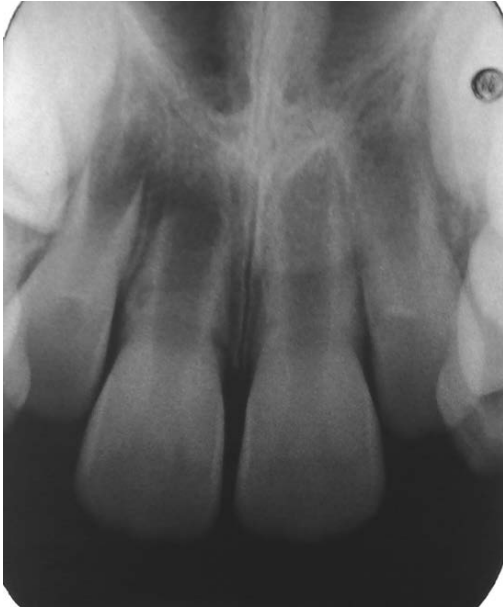

Fig. 2a. Immature tooth 11 with necrotic pulp and periapical lesion in 9-years old patient

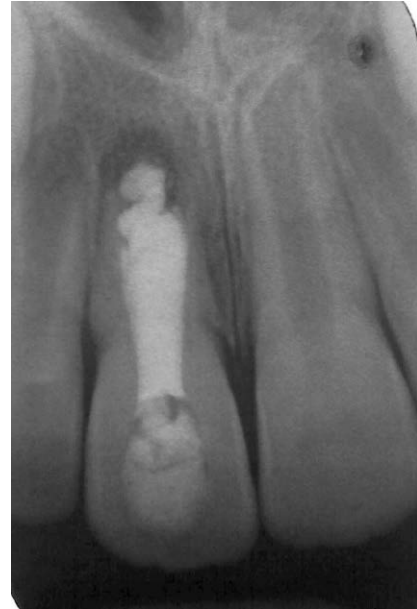


Fig. 2c. Tooth 11 after backfill obturation

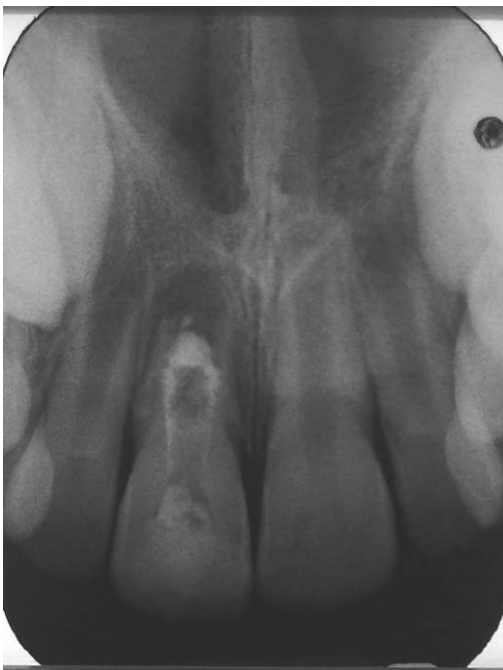

Fig. 2b. Tooth 11 after placement of MTA apical plug

initial examination. A buccal sinus tract was noted near the apex. The radiograph confirmed chronic periapical periodontitis (fig. 1a). After application of rubber dam and endodontic access preparation the procedure of apexification was conducted as described above (figs. 1b, c). At the same visit a portion of collagen sponge and ProRoot MTA material were placed in the canal at the root end. After 7 days canal was backfilled using Obtura system. The follow-up appointments after 6 and 12 months showed proper clinical function of the tooth, healing of sinus tract and absence of clinical symptoms. The radiographic examination

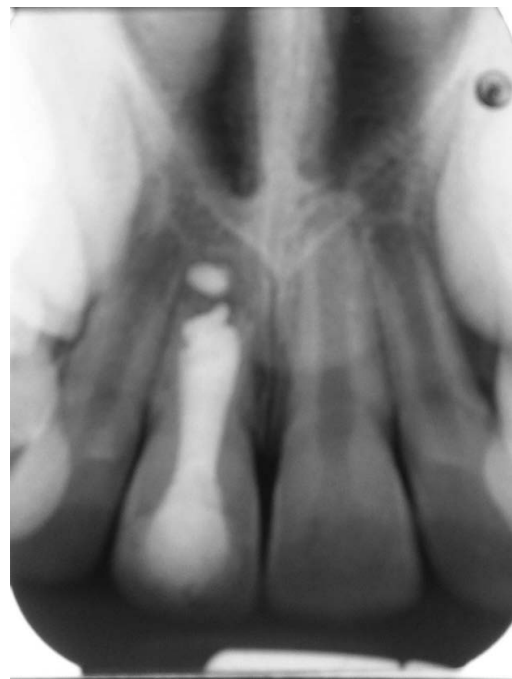


Fig. 2d. Follow-up of tooth 11 after 12 months

after 6 and 12 months revealed the continuous decrease of periapical lesion and formation of apical barrier (fig. 1d).

#### Case 2

A 9-year-old girl with Class II malocclusion had an avulsion of the upper central right incisor. The tooth was replanted after 1 hour extraoral time in saline solution and a decision was made to stabilize the tooth with semi-rigid splint for 2 weeks. Patient missed 2 follow-ups after removing the splint and 4 months after the trauma she was referred to the Department of Pediatric Dentistry suffering from



spontaneous pain. The clinical and radiographic examination showed chronic exacerbated apical periodontitis, however there were no signs of root resorption (fig. 2a). After placing rubber dam and preparing access cavity the root canal was gently instrumented and irrigated with 2% sodium hypochlorite and 0.9% NaCl, dried with

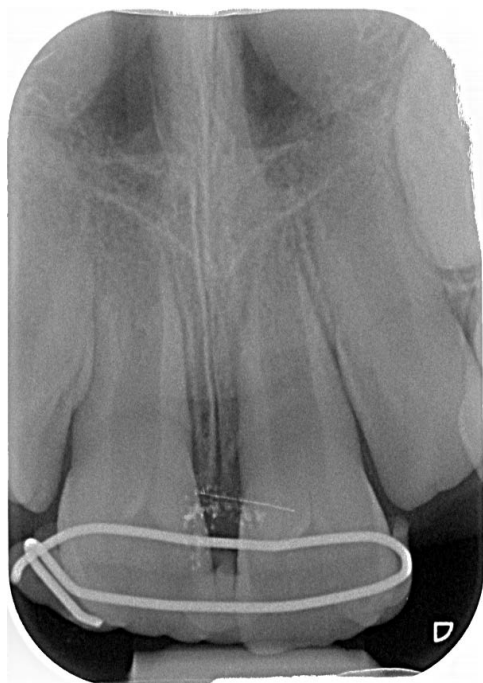


Fig. 3a. Immature tooth 21 immediately after replantation with surgical splint

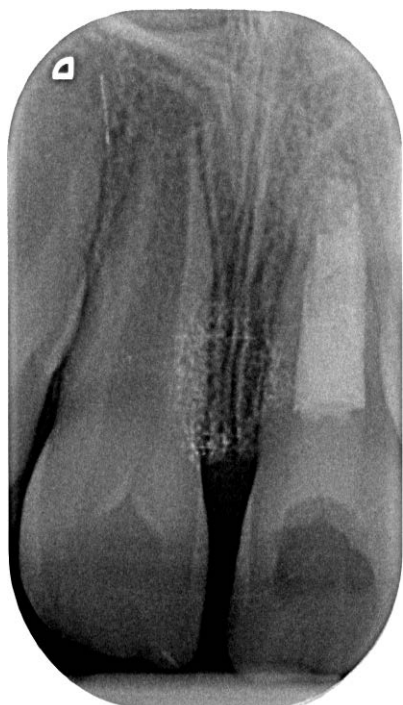

Fig. 3b. Tooth 21 after placement of MTA apical plug and backfill obturation

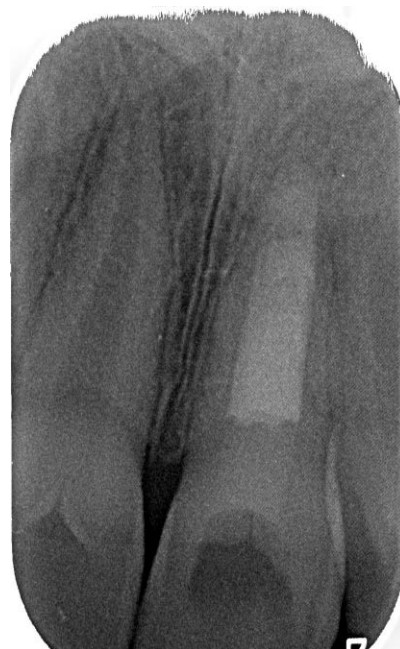
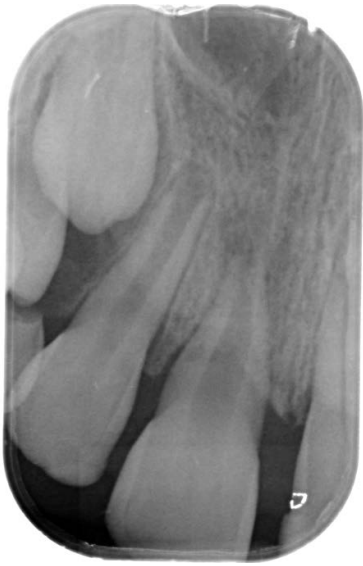
Fig. 3c. Follow-up of tooth 21 after 3 years

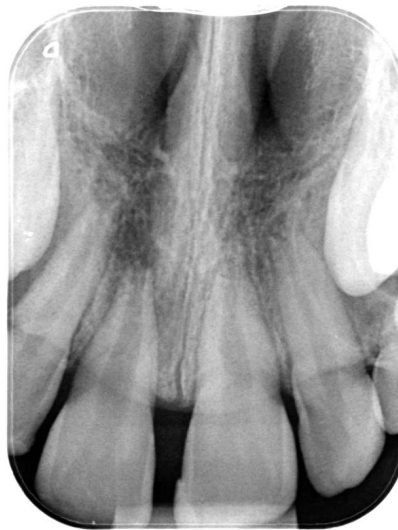standard paper points. Then a calcium hydroxide dressing was applied for 2 weeks period. Before the second appointment, the tooth was asymptomatic and after rinsing with 2% sodium hypochlorite and 0.9% saline solution the apexification was commenced (fig. 2b). Although the procedure was performed under a microscope by an experienced dentist, unfortunately a small amount of MTA apical plug extrusion was noted (fig. 2c). The follow-ups after 6 and 12 months showed no symptoms and no signs of root resorption. The radiographic examination after 6 months showed decrease and after 12 months healing of the periapical lesion (fig. 2d). The creating of apical barrier was incomplete, presumably due to over-filling of the root canal.

### Case 3

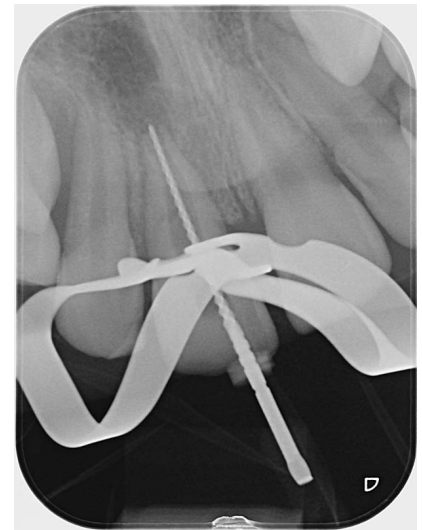A 6.5-year-old boy with Class II malocclusion suffered avulsion of central left maxillary incisor. The tooth was replanted by the child's mother 15 min after injury. In the Department of Pediatric Dentistry surgical wire was removed and semi-rigid splint was placed for 14 days (fig. 3a). Pulp vitality tests after 1, 3 and 6 months were negative. Laser Doppler flowmetry confirmed the pulp necrosis. Apexification procedure was performed with ProRoot MTA as described above, the remaining portion of the canal was filled with thermoplastic gutta-percha and AH Plus Sealer on the next appointment (fig. 3b). A 3-year follow-up radiogram revealed calcified apical barrier in treated tooth 21 and normal further development of the root of the contralateral incisor with healthy pulp (fig. 3c). Clinically, no pain, fistula, tenderness to pressure or percussion mobility, loss of function, ankylosis or other complications after endodontic treatment of the tooth 21 were noted.



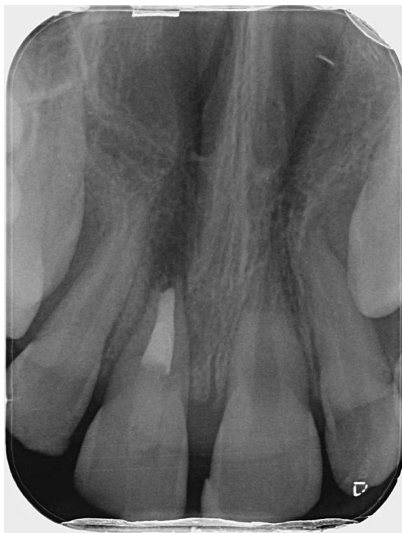**Fig. 4a.** Immature tooth 11 immediately after replantation prior splinting



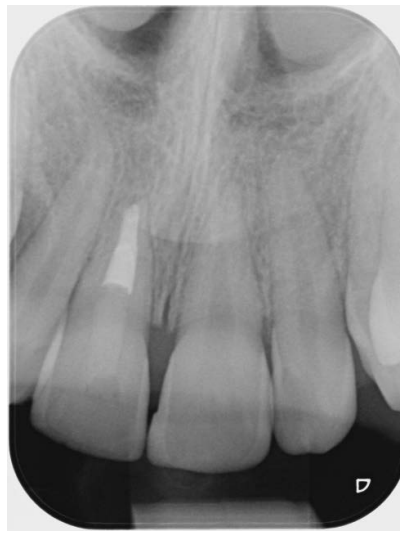**Fig. 4b.** Tooth 11 two-year observation after traumatic injury and replantation (disproportionate root development of central incisors). Decision was made to begin apexification procedure



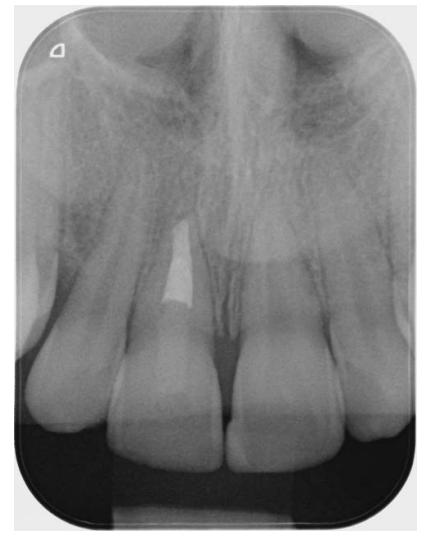**Fig. 4c.** Measurement of working length in tooth 11 root canal with endodontic file



**Fig. 4d.** Tooth 11 after placement of MTA apical plug and backfill obturation



**Fig. 4e.** Follow-up of tooth 11 after 12 months



**Fig. 4f.** Follow-up of tooth 11 after 30 months

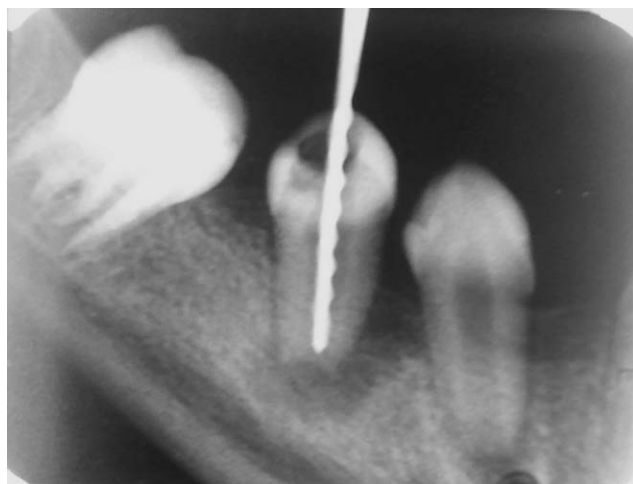#### Case 4

An 8-year-old girl with Class II malocclusion suffered avulsion of maxillary right central incisor. Tooth was replanted within 30 min of the injury (fig. 4a) and the decision was made to stabilize the tooth with semi-rigid splint for 4 weeks due to increased mobility after 2 weeks. Follow-up examinations after 1 month, 3 months, 4 months, 13 months, 18 months and 24 month demonstrated progressive loss of vitality (ethyl chloride test) and decreased root growth relative to contralateral incisor in consecutive radiograms (fig. 4b). Apexification procedure was carried out, pulp

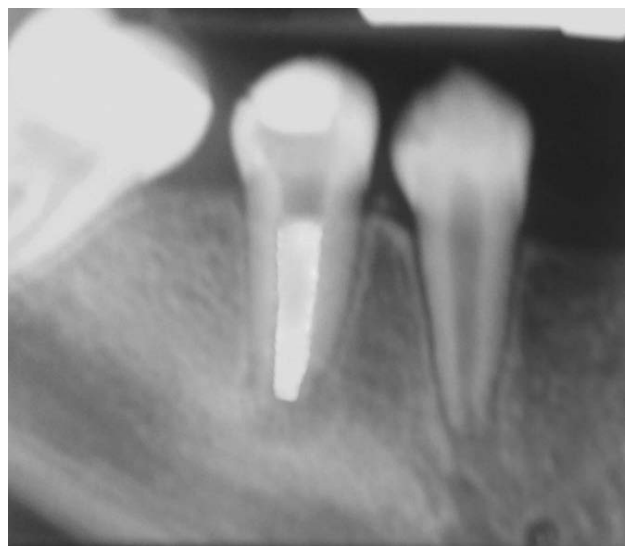extirpation (partial necrosis) and chemomechanical canal debridement according to the previously-described procedure (fig. 4c). Apical portion of the canal was filled with BioMTA (fast setting), the remaining portion was obturated with thermoplastic gutta-percha and AH Plus Sealer (fig. 4d). Clinical and radiological reviews at 3 months, 12 months (fig. 4e), 30 months (fig. 4f) exhibited successful outcome.

#### Case 5

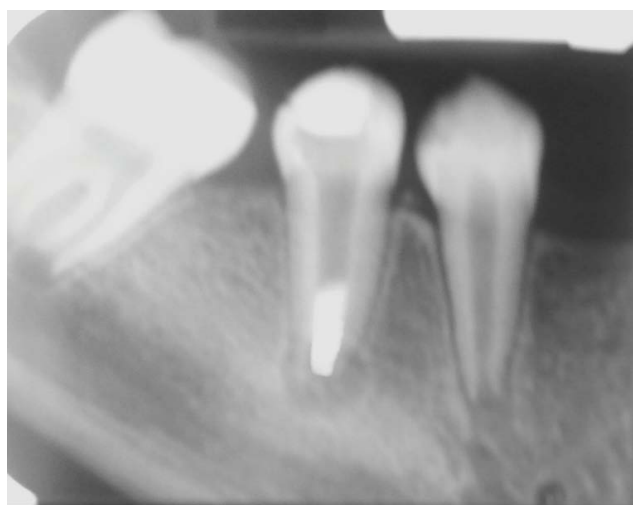
A 13-year-old girl presented a buccal sinus tract in the area of the apex of lower second right premolar. Clinical



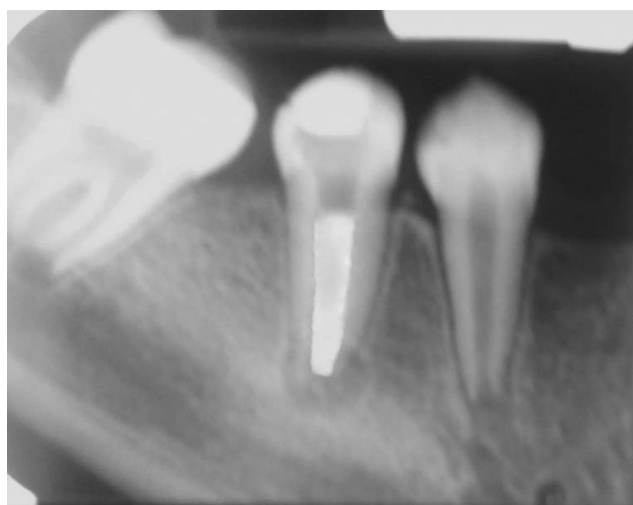**Fig. 5a.** Immature tooth 45 with necrotic pulp and periapical lesion in 13-years old patient. RTG with hand instrument to determine working length



**Fig. 5d.** Follow-up of tooth 45 after 6 months



**Fig. 5b.** Tooth 45 after placement of MTA apical plug



**Fig. 5c.** Tooth 45 after backfill obturation

examination also showed an extensive carious lesion at the distal and occlusal surfaces of tooth. Radiograph revealed chronic periapical periodontitis (fig. 5a). After placing rubber dam and creating access preparation the apexification procedure was carried out according to the protocol described above (figs. 5b, 5c). The follow-up appointment and radiographic examination after 6 months revealed absence of clinical symptoms, healing of the periapical lesion, and formation of the apical barrier (fig. 5d). The patient did not report for further follow-up appointments.

## DISCUSSION

Pulp necrosis in teeth is a common complication of traumatic injuries. Traumatic dental injuries often affect children aged 6-9 with incomplete root formation. The second cause of arrested root formation is caries and its complications (irreversible pulpitis). Presented cases confirmed apexification as effective procedure in immature permanent teeth. Application of MTA significantly reduces the treatment time and minimizes the potential complications connected with the use of calcium hydroxide. The preparations based on calcium hydroxide are placing in the canal only for two weeks to one month to disinfect canal space, after this time root end is closed with MTA material (12). The suitable alternative to MTA in one-visit apexification is the fast setting material Biodentine (Septodont) (14). Apexification with calcium hydroxide is effective, however it requires several appointments. This causes the risk of treatment failure as multiple visits may be unpleasant and difficult to remember for young patients and their parents. The appointments might be forgotten because the teeth often remain asymptomatic (6). It is reported that long-term root canal treatment with calcium hydroxide dressings may influence the mechanical resistance of the tooth and increase the risk of tooth fracture (6). Utilizing MTA enables to avoid such problems. In addition, tooth structure may be strengthened,



when after apex closure the remaining part of root canal is obturated with adhesive composite material instead of gutta-percha.

In endodontics, the smear layer is a thin layer covering canals dentin that forms during instrumentation. Smear layer may be removed with various agents, such as the solution of EDTA or citric acid. Although some authors state that removing smear layer benefits the obturation seal, it is reported that presence of smear layer decreased the micro-leakage of MTA used as orthograde root canal filling (15). Thus in our study the smear layer was not removed from the root canal walls prior to application of MTA.

MTA is quite difficult to handle, so some studies have been made to improve its physical properties. It was proposed to use 10% calcium chloride as an accelerator to ensure MTA more adequate and easy handling consistency and higher luster (16). The addition of calcium chloride does not change MTA biologic properties, but the study only concerns direct pulp capping after pulpotomy so the accelerator was not used in this cases. Placing MTA in the apical foramen is a precise procedure and it had to be performed with the endodontic microscope as it facilitates visualization of the root end (8, 9, 17).

MTA is biocompatible, hard tissue inductive and conductive, nontoxic, noncarcinogenic, nongenotoxic, insoluble in tissue fluids and dimensionally stable. Thanks to above mentioned features MTA has a variety of clinical indications. Nowadays it is recommended for apexification, direct pulp capping, pulpotomy, root canal filling, repair of root perforations and both internal and external resorptions (9, 12, 13, 18-25).

Mente et al. (22) investigated the outcome of endodontic treatment using MTA to create apical plug. According to this study 95% of assessed teeth were fully functional after 30 months, what means that periapical lesions were healed or significantly diminished and the teeth were asymptomatic. Creating apical barrier with MTA, when compared to multi-visit apexification with calcium hydroxide,

demonstrated higher rate of success during clinical and radiographic follow-ups (20).

The novel alternative to apexification in treating immature teeth with a necrotic pulp is the regenerative endodontic therapy involving revascularization or autologous platelet-rich plasma and scaffolds to elicit host stem cells is defined as "biologically based procedures designed to physiologically replace damaged tooth structure, including dentin and root structures, as well as pulp-dentin complex" (25). This method of treatment has the unique potential advantage, allows for the further growth of the root and the growth of its wall thickness as in apexogenesis (12, 25-33). However, there is no obvious benefit to providing revascularization procedure to teeth with thick enough dentinal walls to withstand a fracture, in these cases apexification is the most optimal endodontic treatment because it is a more predictable method in terms of obtaining a positive treatment outcome (25).

Tooth injuries leading to pulp necrosis and the need for apexification treatment often occur in children with malocclusion as it was in four cases presented in this study. There is the question of how orthodontic treatment affects the condition of endodontically treated teeth especially with the apexification method. The results of retrospective study conducted by Keinan et al. (34) showed that orthodontic movement of immature traumatized teeth after apexification appears to be safe. The authors observed minor root resorption in teeth treated endodontically with MTA apexification method than in healthy teeth with vital pulp. The endodontically treated teeth are less susceptible to apical root resorption than vital teeth after orthodontic treatment (35).

## CONCLUSIONS

Apexification with MTA is a valuable alternative to methods utilizing calcium hydroxide. It is successful optimal treatment in endodontic therapy of immature teeth with necrotic pulp.

## KONFLIKT INTERESÓW

Brak konfliktu interesów

## CORRESPONDENCE

\*Lidia Postek-Stefańska  
Katedra i Zakład Stomatologii  
Wieków Rozwojowego  
Śląski Uniwersytet Medyczny  
w Katowicach  
Pl. Traugutta 2, 41-800 Zabrze  
tel.: +48 (32) 271-36-12  
lstefanska@sum.edu.pl

## REFERENCES

1. Giuliani V, Baccetti T, Pace R, Pagavino G: The use of MTA in teeth with necrotic pulps and open apices. *Dent Traumatol* 2002; 18: 217-221.
2. Postek-Stefańska L, Szczepańska J, Olczak-Kowalczyk D: Specyfika leczenia chorób miazgi niedojrzałych zębów stałych. [W:] Olczak-Kowalczyk D, Szczepańska J, Kaczmarek U (red.): *Współczesna stomatologia wieku rozwojowego*. Med Tour Press International, Otwock 2017: 524-542.
3. Fuks AB: *Pediatric Endodontics. Current concepts in pulp therapy for primary and young permanent teeth*. Springer, London 2016.
4. Pradhan DP, Chawla HS, Gauba K, Goyal A: Comparative evaluation of endodontic management of teeth with unformed apices with mineral trioxide aggregate and calcium hydroxide. *J Dent Child* 2006; 73: 79-85.
5. Kleier DJ, Barr ES: A study of endodontically apexified teeth. *Endod Dent Traumatol* 1991; 7: 112-117.
6. Witherspoon DE, Small JC, Regan JD, Nunn M: Retrospective analysis of open apex teeth obturated with mineral trioxide aggregate. *J Endod* 2008; 34: 1171-1176.
7. Rafter M: Apexification – a review. *Dent Traumatol* 2005; 21: 1-8.



8. Blome B, Sobarzo V: Sukces i niepowodzenie po zamknięciu wierzchołka preparatem MTA. *Endodoncja* 2009; 2: 86-93.
9. Bogen G, Kuttler: Mineral Trioxide Aggregate obturation: A review and case series. *J Endod* 2009; 35: 777-790.
10. Postek-Stefańska L, Jodłowska A, Pająk J et al.: Osteogenic properties of the materials used to apical barrier formation in experimental study on rabbits. *Pol J Environ Stud* 2007; 16: 403-407.
11. Andresen JO, Farik B, Munksgaard EC: Long-term calcium hydroxide as a root canal dressing may increase risk of root fracture. *Dent Traumatol* 2002; 18: 134-137.
12. American Academy of Pediatric Dentistry: Pulp therapy for primary and immature permanent teeth. *The Reference Manual of Pediatric Dentistry*. Chicago III; American Academy of Pediatric Dentistry 2021: 399-407.
13. Magro MG, Kuga MC, Ricci WA et al.: Endodontic management of open apex teeth using lyophilized collagen sponge and MTA cement: Report of two cases. *Iran Endod J* 2017; 12: 248-252.
14. Balasubrahmaniam A, Sabna BS, Ramesh Kumar M, Jayasree S: One visit apexification using a novel dental material Biodentine. A case report. *J Dent Med Sci* 2014; 13: 90-92.
15. Yildirim T, Orucoglu H, Cobankara FK: Long-term evaluation of the influence of smear layer on the apical sealing ability of MTA. *J Endod* 2008; 34: 1537-1540.
16. Bortoluzzi EA, Broon NJ, Bramante CM et al.: MTA with or without calcium chloride in pulpotomy. *J Endod* 2008; 34: 172-175.
17. Mazur T, Postek-Stefańska L: Leczenie endodontyczne zębów stałych z niezakończonym rozwojem korzenia z powodu uszkodzeń pourazowych. *Magazyn Stomatol* 2006; 11: 10-13.
18. Parirokh M, Torabinejad M: Mineral Trioxide Aggregate: A comprehensive literature review – part I: chemical, physical and antibacterial properties. *J Endod* 2010; 36: 16-27.
19. Łuczaj-Cepowicz E, Marczuk-Kolada G, Waszkiel G: Możliwości zastosowania klinicznego nowego materiału mineral trioxide aggregate (MTA) – przegląd piśmiennictwa. *Nowa Pediatria* 2008; 4: 62-66.
20. Yilmaz HG, Kalender A, Cengiz E: Use of mineral trioxide aggregate in the treatment of invasive cervical resorptions: a case report. *J Endod* 2010; 36: 160-163.
21. Yildirim T, Gencoglu N: Use of mineral trioxide aggregate in the treatment of horizontal root fractures with a 5-year follow-up: report of a case. *J Endod* 2009; 35: 292-295.
22. Mentel J, Hage N, Pfeifferle T et al.: Mineral Trioxide Aggregate apical plugs in teeth with open apical foramina: a retrospective analysis of treatment outcome. *J Endod* 2009; 35: 1354-1358.
23. Bonte E, Beslot A, Boukpepsi T et al.: MTA versus Ca(OH)<sub>2</sub> in apexification of non-vital immature permanent teeth: a randomized clinical trial comparison. *Clin Oral Invest* 2015; 19: 1381-1388.
24. Ćwiklak K, Szczepańska J: Zastosowanie MTA w zębach stałych niedojrzałych – przegląd piśmiennictwa. *Nowa Stomatol* 2012; 1: 19-23.
25. Murray PE: Review of guidance for the selection of regenerative endodontics, apexogenesis, apexification, pulpotomy and other endodontic treatments for immature permanent teeth. *Int Endod J* 2022; 00: 1-12.
26. Namour M, Theys S: Pulp revascularization of immature permanent teeth: a review of the literature and a proposal of a new clinical protocol. *Scientific World Journal* 2014: 737503.
27. Xie Y, Lu F, Hong Y et al.: Revascularisation versus apexification for treatment of immature teeth based on periapical healing and root development: a systematic review and meta-analysis. *Eur J Paediatr Dent* 2021; 22(3): 207-214.
28. De Souza Araujo PR, Silva LB, Dos Santos Neto AP et al.: Pulp revascularization: a literature review. *Open Dent J* 2017; 10: 48-56.
29. Galler KM, Krastl G, Simon S et al.: European Society of Endodontology position statement: revitalization procedures. *Int Endod J* 2016; 49: 717-723.
30. Wikström A, Brundin M, Lopes MF et al.: What is the best long-term treatment modality for immature permanent teeth with pulp necrosis and apical periodontitis? *Eur Arch Paediatr Dent* 2021; 22(3): 311-340.

31. Jeeruphan T, Jantarat J, Yanpiset K et al.: Mahidol study 1: comparison of radiographic and survival outcomes of immature teeth treated with either regenerative endodontic or apexification methods: a retrospective study. *J Endod* 2012; 38: 1330-1336.
32. Pazera R, Szczepańska J: Nowoczesna metoda leczenia martwicy miazgi w zębach z niekształtowanym wierzchołkiem – rewaskularyzacja miazgi. Część I. *Nowa Stomatol* 2014; 1: 37-40.
33. Pazera R, Szczepańska J: Nowoczesna metoda leczenia martwicy miazgi w zębach z niekształtowanym wierzchołkiem – rewaskularyzacja miazgi. Część II. *Nowa Stomatol* 2014; 2: 16-20.
34. Keinan D, Asbi T, Shalish M, Slutzky-Goldberg I: An assessment of the effects of orthodontic treatment after apexification of traumatized immature permanent teeth: a retrospective study. *J Endod* 2022; 48: 96-101.
35. Ioannidou-Marathiotou I, Papadopoulos MA: Root resorption if endodontically treated teeth following orthodontic therapy: a meta-analysis. *Clin Oral Invest* 2013; 17: 1733-1744.

**nadesłano:**

6.04.2022

**zaakceptowano do druku:**

27.04.2022