

## The effectiveness of formocresol amputation in deciduous molars – a retrospective study\*\*

<sup>1</sup>Doctoral Studies, Department of Paediatric Dentistry, Medical University of Łódź

<sup>2</sup>Department of Paediatric Dentistry, Medical University of Łódź

Head of Department: Professor Joanna Szczepańska, MD, PhD

### KEYWORDS

formocresol pulpotomy, formocresol, primary teeth

### SUMMARY

**Introduction.** The treatment of carious denudation of pulp and irreversible partial pulp inflammation is pulpotomy. In this method formocresol was used as the “gold standard”.  
**Aim.** Assessment of the effectiveness of the use of formocresol in pulpotomy in deciduous teeth.

**Material and methods.** Formocresol amputation performed in 2010-2012 in children born in 2006-2007 were analysed. The consent of the Bioethical Committee at the Medical University of Łódź as well as written consent from all the subject/parents of all the subjects/legal guardians of all the subjects were obtained.

**Results.** In this research, the amputation in 102 deciduous teeth, including 49 first and second upper molars, and 53 lower molars, performed on 64 children were analysed. In 102 amputation cases 78 were caused by carious denudation of pulp and 24 by irreversible partial pulp inflammation without visible denudation of pulp. 37 patients underwent pulpotomy in 1 tooth, 19 patients needed it in 2 teeth, 6 patients in 3 teeth, 1 patient in 4 teeth, and 1 patient in 5 molars. The pulpotomy was repeated because of the glass-ionomer lost in 19 cases. In total 63 teeth were extracted, including 25 at the right time and 38 too early. During the last oral examination held 2016/2017, 31 out of 102 teeth were still on place. The lack of 8 teeth without the presence of permanent successors was reported. The analysis of 102 cases showed the average of 2.5 years period of the teeth maintenance following the formocresol pulpotomy.

**Conclusions.** Retrospective analysis of the use of formocresol in pulpotomy in deciduous teeth proved clinical success of this material, which provided the maintenance of the teeth with the pulpitis for 2 to 3 years after the amputation.

### INTRODUCTION

One of the main tasks of paedodontics is maintenance of full primary dentition until its physiological resorption. Premature loss of primary teeth results in serious disorders in a stomatognathic system such as malocclusions, disorders in jaw development and an activity of a temporo-mandibular joint and a loss of a correct occlusion height (1, 2). It also

contributes to speech disorders, mastication disorders and defects in appearance, which may contribute to complexes and lack of acceptance in the environment.

Negligence in child's oral hygiene, insufficient education for parents, irregular visits at the dentist, a diet rich in carbohydrates, and the structure of primary teeth make them prone to the development of carious processes. In the case of carious or posttraumatic denudation of pulp, pulpotomy

\*\*Paper financed with the funds from a research project for young scientists and doctoral students at the Medical University of Łódź 502-03/2-043-02/502-24-060.

is conducted in order to prevent early extraction (3). Pulpotomy may be conducted when there is reversible or irreversible partial pulp inflammation. It is contraindicated when there are long spontaneous dental pains, bleedings difficult to staunch, and changes in periapical tissues (4). Amputation is completed by the extraction of chamber pulp with irreversible inflammation and covering vital pulp or pulp with reversible inflammation with a special agent (3).

One of the agents applied in such treatment is formocresol. A mixture of zinc oxide, eugenol and formocresol was first used in pulpotomy of deciduous teeth in 1930 by Sweet (5). Buckley's formula consists of 19% of formocresol and 35% of cresol in a solution of 15% of glycerine and 31% of water. Diluted 1:5, it is placed in the chamber for 5 minutes, next the bottom of the chamber is covered with formocresol paste and cement, and a cavity is tightly filled in. When cooperation with a child is difficult or there are problems in obtaining hemostasis, a cotton ball with formocresol may be left in for seven days (4). Formocresol is antibacterial and mummifying, it has an impact on the activity of hyaluronidase (6). For over 80 years, it was a "golden standard" and used by most of the dentists. The effectiveness of using formocresol in pulpotomy was estimated 70-97% (7). Rolling and Thylstrup (8) proved that this effectiveness decreases with time.

## AIM

The aim of the research was a retrospective analysis of an impact of formocresol amputation on the maintenance of primary molars in an oral cavity.

## MATERIAL AND METHODS

Retrospective research was conducted on the basis of a medical record at the Department of Paediatric Dentistry at the Medical University of Łódź, Poland. Access to the patients' medical history was approved by the management of the Central Teaching Hospital of the Medical University of Łódź. In the article, no personal data of patients were revealed. The consent of the Bioethical Committee at the Medical University of Łódź as well as written consent from all the subject/parents of all the subjects/legal guardians of all the subjects were obtained.

This research covered formocresol amputations of primary molars in patients born in the years 2006 and 2007, i.e. between the age of 3 and 6, who had been treated with this method at the Department of Paediatric Dentistry in the years 2010-2012 with the consent of a parent/legal guardian. Cases had to meet the following criteria in order to be qualified for the analysis:

- carious denudation of pulp or partial irreversible pulp inflammation,
- available record of treatment of a given tooth until 2016/17 (or until exfoliation).

Criteria for the exclusion from the research were:

- incomplete record of treatment,

- total irreversible pulp inflammation,
- changes in periapical tissues,
- dental crown destroyed by caries, with no possibility of reconstruction.

In each case, amputation was conducted in accordance with current standards. After working on the cavity and chamber, a tampon with formocresol was placed in the chamber. In cases of pain and exudate, formocresol paste (formocresol + zinc oxide + eugenol) was put at the bottom of the chamber. Next, the chamber was filled in with polycarboxylic cement Adhesor and the cavity – with a glass-ionomeric material. A card of analysis of dental surgery success/failure contains the assessment of the following elements: reason for the surgery, time of tooth preservation in an oral cavity since the surgery, complications such as swelling, fistula, abscesses, pathological changes in X-ray imaging, spontaneous aches, fractures in a crown, which are reasons for premature extractions. Child's age, at which extraction was completed, is also taken into account as well as the time between the surgery and extraction. The number of patients, who needed the surgery to be repeated due to the loss of the filling, and the number of teeth with amputation in one patient, were summed up.

## RESULTS

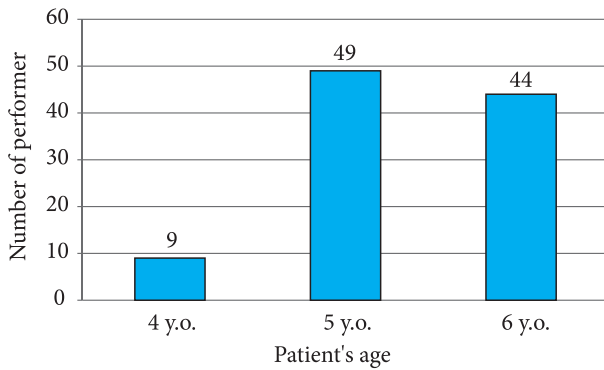
Formocresol amputation was performed in 242 teeth in 195 children in the Department of Paediatric Dentistry at the Medical University of Łódź in the years 2010-2012. The final analysis covers 102 teeth in 64 children. Other cases were excluded due to the incomplete history of treatment (until the eruption of permanent teeth or premature extraction).

Amputation was performed in 49 baby upper first and second molars and 53 lower ones. There were 78 cases of carious denudation of pulp and in the other 24 cases, irreversible partial pulp inflammation was observed without visible denudation of pulp.

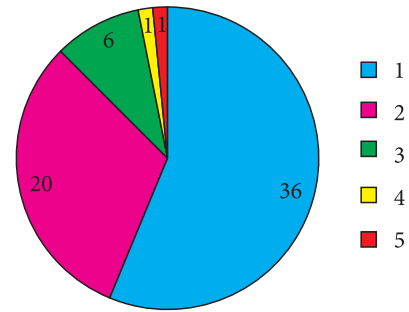
At the first step (putting a cotton ball with a therapeutic agent for seven days), formocresol was used in 78 cases, Cresophene – in 22 cases and Caustinerf – in two teeth. Nine amputations were performed in four-year old patients, forty-nine – in five-year old patients, and forty-four – in six-year old patients (fig. 1).

One pulpotomy procedure was performed in 37 people, 2 teeth needed to be amputated in 19 people, 3 – in 6 patients, 4 – in 1 patient and 5 baby molars in 1 patient (fig. 2). Pulpotomy was repeated as a result of a loss of glass-ionomeric filling in 19 cases.

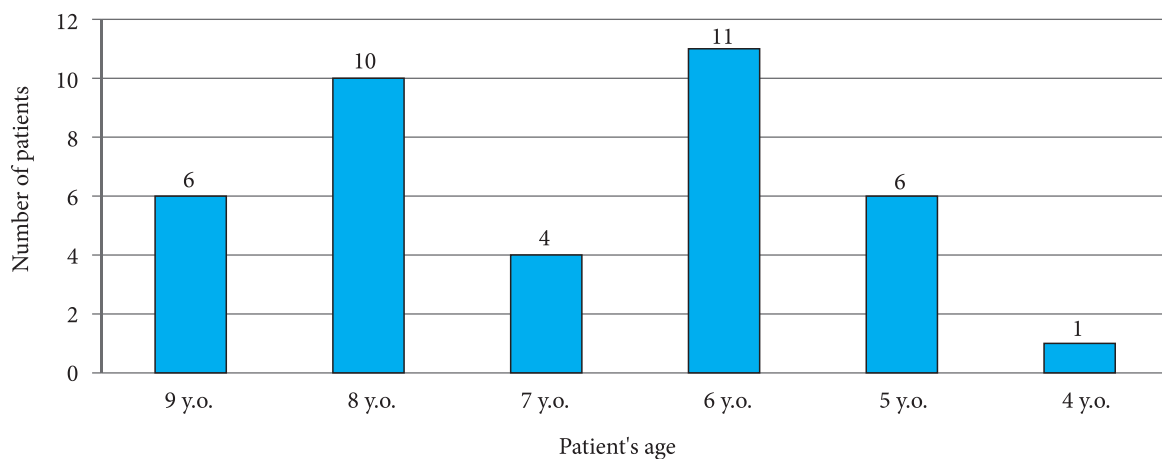
All in all, 63 teeth were pulled, including 25 on time: 14 as a result of development of a permanent tooth, 11 – due to physiological resorption. 38 teeth were extracted prematurely: 6 teeth in the 9<sup>th</sup> year of age, 10 teeth in the 8<sup>th</sup> year of age, 4 teeth in the 7<sup>th</sup> year of age, 11 teeth in the 6<sup>th</sup> year of age, 6 teeth in the 5<sup>th</sup> year of age, and 1 tooth in the 4<sup>th</sup> year of age (fig. 3). 24 among 38 teeth were referred



**Fig. 1.** Number of performed formocresol amputations in various age groups



**Fig. 2.** Classification of patients according to the number of performed formocresol amputations from 1 to 5



**Fig. 3.** Number of patients in accordance with age, in whom premature extraction was performed

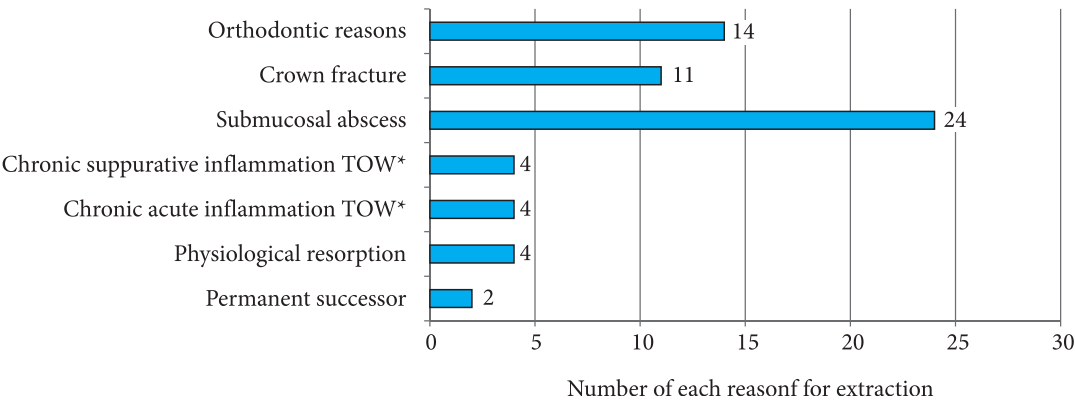
for extraction due to symptoms characteristic to chronic acute periodontitis such as spontaneous ache or changes in periapical tissues in clinical or radiological assessment. In 4 cases, tooth crowns were fractured with no possibility of their restoration. Further 4 primary molars were removed due to a purulent exudate (found after removal of filling) or presence of fistulas (lat. *periodontitis chronica purulenta*). In four cases, submucosal abscess developed. Another two primary teeth were extracted due to orthodontic reasons (fig. 4). Furthermore, 8 teeth were missing without permanent successor yet there was no information about the reason for their extraction.

Time of teeth preservation in an oral cavity differed according to age at which amputation treatment was performed. For the first molars it was: 2 years and 5 months in 6-year-olds, 2 years and 8 months in 5-year-olds, 2 years and 11 months in 4-year-olds. For the first upper molars and second upper and lower molars it was: 2 years in 6-year-olds, 2 years and 9 months in 5-year-olds, 2 years and 6 months in 4-year-olds.

In the last research conducted at the turn of 2016 and 2017, 31 among 102 teeth were present in an oral cavity, which is 30.39%. An analysis of 102 cases showed a mean of 2.5 year of teeth preservation in an oral cavity after a formocresol amputation. In table 1, a mean time of teeth preservation in an oral cavity is presented, according to patient's age at which the surgery was performed.

## DISCUSSION

Cariou process in primary teeth is fast. It is boosted by the structure of deciduous teeth as well as bad eating and hygiene habits of a young patient. Carious denudation of pulp or an irreversible partial or entire crown pulp inflammation are recommendations for the amputation. Pulp denudation is observed more often, which is also confirmed in modern research, according to which 76% of reasons for pulpotomy are cases of pulp denudation. An aim of this surgery is preservation of a primary tooth in an oral cavity with healthy pulp until the time of eruption of a permanent successor.



**Fig. 4.** Reasons for the extraction if teeth in which formocresol amputation was performed  
TOW – periapical tissue

**Tab. 1.** Mean time of teeth preservation in an oral cavity after amputation according to patient’s age at which the surgery was performed

Patient’s age at which pulpotomy was performed	Number of people	Mean time of tooth preservation in an oral cavity after amputation	
		First lower molars.	Firt upper molars. Second upper and lower molars.
4 y.o.	9	2 years and 11 months	2 years and 6 months
5 y.o.	49	2 years and 8 months	2 years and 9 months
6 y.o.	44	2 years and 2 months	2 years

Dental surgeries on primary teeth in kindergarten and early primary school children is very difficult due to patient’s age and frequent lack of cooperation. Visits should be as short as possible. Therefore, in these kids, in the cases of both reversible and irreversible partial pulp inflammations, and sometimes in the cases of necrosis without complications in periapical tissues, complete amputation is performed.

When a tooth crown is damaged severely as well as after endodontic treatment of primary teeth, the best reconstruction is steel crowns which provide the best durability (9). Their application is time consuming and requires cooperation with a patient, but the time needed for their application and cementation is usually equal with the time needed for the application of amalgamate filling (9). In the modern research, final filling was performed with a conventional glass-ionomeric material due to a high risk of caries. It was lost in 19 cases, so another application of formocresol paste, Adhesor or filling was required. No changes were observed in the time of preservation of these 19 teeth in an oral cavity, and other teeth. It was certainly due to a short time between a loss of filling, and a visit and performance of another filling.

Caustinerf forte preparation, applied at the first stage of endodontic treatment, is used for painless devitalisation of pulp, contains lidocaine and paraformaldehyde. In other

cases, Cerosphene was applied which is used for disinfection of root canals and contains dexamethasone, thymol, parachlorophenol and racemic camphor.

Root resorption in the first primary molars begins in the 6<sup>th</sup> year of age, and of the second primary molars in the 7<sup>th</sup> year of age. Exfoliation of the first lower primary molars occurs in the 9<sup>th</sup> year of age, and of the first upper molars and the second upper and lower molars – in the 10<sup>th</sup> year of age. Mean times of various tooth groups loss determined in epidemiological research, served as a basis in this research for the determination of the time when these teeth were lost in comparison to physiological loss of primary teeth. It turned out that as a result of amputation, the time of tooth preservation in an oral cavity was similar in accordance with age and was: from 2 years for the first lower molars in 6-year-olds to 2 years and 11 months in 4-year-olds or to 2 ears and 9 months in 5-year-olds. However, in the case of 4-year-olds, the loss of the first lower molars was premature by ca. 2 years and of the first upper molars and the second upper and lower molars – by 3.5 years. Local factors which enhance resorption of deciduous teeth are inter alia: pulp inflammation, endodontic treatment and formocresol amputation which, according to numerous researchers, also accelerates resorption of primary teeth roots and the eruption of permanent teeth (4, 6, 10). These elements may also contribute to the premature loss of primary teeth in individual research.

It has long been known that formocresol is devitalising for canal pulp (11). After formocresol amputation, mumification of 1/3 of a crown part of canal pulp, chronic inflammation of central canal pulp and intact healthy pulp in 1/3 of a tooth apex were found. Other researchers found total necrosis of canal pulp (12). Berger (13) found necrosis and presence of granulation tissue in 1/3 of an apex part of canal pulp. Similarly in our research, 32 teeth were removed due to inflammatory changes in apex tissues. A most frequent reason for failures in amputation treatment is an incorrect diagnosis, when irreversible inflammation also covers root pulp (6).

According to WHO, International Agency for Research on Cancer (IARC), Health Canada, Agency for Toxic Substances and Disease Registry in the U.S., Department of Health and Human Services and U.S. Environmental Protection Agency formaldehyde is cancerogenic and toxic to people (6). In IARC monography, formaldehyde is presented as an agent which causes the development of cancer in an oral and nasal cavity (of rare occurrence in developed countries). Moreover, it suggests that there is little evidence to the development of cancer in a nasal cavity and paranasal sinuses and "strong yet insufficient evidence" to the development of leukemia as a result of formocresol activity (14). According to the research on animals, formaldehyde and tricresol enter a cardiovascular system through an apex hole within several minutes after formocresol amputation (15). Some researchers also discovered a harmful impact of formocresol on permanent tooth buds (1, 6).

Supporters of formocresol claim that there are no documented cases of distribution of this agent in the organism and of any pathological changes in tissues after application of this agent in humans. What is more, doses of this substance applied to animals were much higher than those used for amputation in people (15). Kahl et al. (15) conducted research on 30 children and performed 85 pulpotomies. Blood samples were taken before, during and after a surgery. Levels of formaldehyde and cresol were analyzed with gas chromatography - mass spectrometry. Levels of both formaldehyde and cresol were impossible to detect in all the analyzed samples. All samples collected during and after a surgery contained benzyl alcohol (a product of cresol metabolism) at a concentration from 0 to 1 mg/ml. Benzyl alcohol is neither mutagenic nor carcinogenic. Acceptable daily intake of it according to WHO is 5 mg/kg. As the amount of benzyl alcohol in the samples was much lower than acceptable daily intake, it is not dangerous to patients. According to the research by Kahl et al. (15) a dose of formocresol applied in amputations is not a risk for a young patient. In the research on metabolism, pharmacokinetics and cancerogenic of formaldehyde, Milnes (16) proved that it is not a strong carcinogen for people on condition that it is used in reasonable doses (an estimated dose of formocresol applied in one pulpotomy (dissolved 1:5, placed on a cotton ball

no. 4 and pressed dry) is from 0.02 to 0.1 mg – author's calculations). So far, no correlation was found between application of formocresol in amputation surgeries and the development of cancer (17).

An aim of the research by Zarzar et al. (18) was to determine an impact of formocresol used in amputation on blood lymphocytes. Blood samples were collected before a surgery and 24 hours after the surgery from 20 adolescent patients. Mutagenic influence of formocresol on lymphocytes was found in one person. According to authors, formocresol is not strongly mutagenic, yet the research should be repeated on a larger group of people with more than one amputation, as in many cases this surgery is performed only on one tooth in a given patient (18). Our research included 27 people with more than one formocresol amputation and in one of these people 5 such surgeries were performed.

Due to reports about toxic and cancerogenic influence of formocresol, an alternative substance was looked for – the one which would be equally efficient yet without further complications (19). An ideal agent should be biocompatible, antibacterial, should not irritate canal pulp or negatively influence periapical tissues or permanent tooth buds (6, 11). Trairatvorakul and Koothiratrakarn (19) compared the activity of calcium hydroxide and formocresol. They found that both materials demonstrate similar efficiency. After application of both formocresol and calcium hydroxide, complications such as internal or external resorptions, and changes in periapical tissues were rare. The authors proved that, unlike calcium hydroxide, application of formocresol does not result in the development of a dentin bridge. However, in the research by Jose et al. (11), a slightly mineralized dentine bridge developed after application of formocresol. What is more, in most of the cases formocresol amputation, partial or total obliteration of canal pulp occurred (19). On the basis of the research by Rolling and Lambjerg-Hansen, it was observed that obliteration is a typical response of pulp to the activity of formocresol. Obliteration of canal pulp often occurs after application of formocresol but also of calcium sulphate (20). According to Fuks et al. (17), calcium hydroxide is less effective than formocresol. After application of this material, more failures are observed than in the cases of formocresol, calcium sulphate, electrocauterization and MTA (9). Application of calcium hydroxide is connected with a risk of internal resorption development (6). When comparing the effectiveness of sodium hypochlorite and formocresol, Ruby et al. (21) discovered that their effectiveness is similar in a clinical and radiological assessment. An analogous result was obtained by Shabzendedar et al. (22). Fuks et al. (17) proved that ferrous sulphate is more effective than formocresol (93 vs 84%). Nevertheless, its application of ferrous sulphate contributed to the development of internal resorptions and obliteration of canal pulp more than application of formocresol. There

are no reports about a toxic or dangerous impact of ferrous sulphate on humans (23). Liu (24) found that use of neodymium-YAG laser in pulpotomy is more effective than formocresol. Similarly, better effects are observed after application of MTA (5). However, application of MTA is connected with high costs, which limits its use, especially in public dental clinics (7, 19). Single-stage formocresol amputation takes 5 minutes, using MTA requires 2 visits and the time of application is ca. 15 minutes (6). Jose et al. (11) compared the activity of formocresol and calcium-phosphate cement (CPC) and found that CPC more effective than formocresol. CPC is biocompatible with pulp, simulates processes of recovery and dentine formation without necrosis points. However, British Society of

Paediatric Dentistry recommends application of materials other than formocresol in pulpotomy, such as MTA, ferrous sulphate (25).

## CONCLUSIONS

Formocresol amputation, which has so far been a "golden standard", allowed for the avoidance of primary tooth extraction, preserving a place for a permanent successor and lowering the risk of the development of malocclusion. A retrospective analysis of using formocresol in amputation of primary teeth confirmed clinical effectiveness of this preparation, which allowed for the preservation of a primary tooth with pulp inflammation in an oral cavity for 2.5 year after the surgery.

## CONFLICT OF INTEREST

None

## CORRESPONDENCE

\*Joanna Szczepańska  
Zakład Stomatologii Wieku Rozwojowego  
Uniwersytet Medyczny w Łodzi  
ul. Pomorska 251, 92-213 Łódź  
tel.: +48 (42) 675-75-16  
joanna.szczepanska@umed.lodz.pl

## REFERENCES

1. Godhi B, Sood PB, Sharma A: Effects of mineral trioxide aggregate and formocresol on vital pulp after pulpotomy of primary molars: an in vivo study. *Contemp Clin Dent* 2011; 2: 296-301.
2. Pimenta HC, Borges AH, Bandeca MC et al.: Antimicrobial activity of filling materials used in primary teeth pulpotomy. *J Int Oral Health* 2015; 7: 54-57.
3. Olatosi OO, Sote EO, Orenuga OO: Effect of mineral trioxide aggregate and formocresol pulpotomy on vital primary teeth: a clinical and radiographic study. *Niger J Clin Pract* 2015; 18: 292-296.
4. Szczepańska J, Olczak-Kowalczyk D, Postek-Stefańska L: Leczenie chorób miazgi zębów mlecznych. [W:] Olczak-Kowalczyk D, Szczepańska J, Kaczmarek U (red.): *Współczesna stomatologia wieku rozwojowego*. Wyd. I. Med Tour Press International, Otwock 2017: 511-523.
5. Yildirim C, Basak F, Akgun OM et al.: Clinical and radiographic evaluation of the effectiveness of formocresol, mineral trioxide aggregate, portland cement, and enamel matrix derivative in primary teeth pulpotomies: a two year follow-up. *J Clin Pediatr Dent* 2016; 40: 14-20.
6. Węglarz A, Olczak-Kowalczyk D: Alternatywy dla użycia formokrezolu w leczeniu chorób miazgi w uzębieniu mlecznym – przegląd piśmiennictwa. *Nowa Stom* 2015; 2: 65-72.
7. Walker LA, Sanders BJ, Jones JE et al.: Current trends in pulp therapy: a survey analyzing pulpotomy techniques taught in pediatric dental residency programs. *J Dent Child (Chic)* 2013; 80: 31-35.
8. Rolling I, Thylstrup A: A 3-year clinical follow-up study of pulpotomized primary molars treated with the formocresol technique. *Scand J Dent Res* 1975; 83: 47-53.
9. Winters J, Cameron AC, Widmer RP: Leczenie chorób miazgi zębów mlecznych oraz stałych niedojrzałych. [W:] Cameron AC, Widmer RP (red.): *Stomatologia dziecięca*. Wyd. III. Elsevier, Wrocław 2008: 95-114.
10. <https://www.medme.pl/leki/formokrezol,5912.html>.
11. Jose B, Ratnakumari N, Mohanty M et al.: Calcium phosphate cement as an alternative for formocresol in primary teeth pulpotomies. *Indian J Dent Res* 2013; 24: 522.
12. Sonmez D, Sari S, Cetinbas T: A comparison of four pulpotomy techniques in primary molars: a long-term follow-up. *J Endod* 2008; 34: 950-955.
13. Berger JE: Pulp tissue reaction to formocresol and zinc oxide-eugenol. *J Dent Child (Chic)* 1965; 32: 13-28.
14. International Agency for Research on Cancer. Press release no. 153; <http://www.iarc.fr/en/media-centre/pr/2004/pr153.html>.
15. Kahl J, Easton J, Johnson G et al.: Formocresol blood levels in children receiving dental treatment under general anesthesia. *Pediatr Dent* 2008; 30: 393-399.



16. Milnes AR: Persuasive evidence that formocresol use in pediatric dentistry is safe. J Can Dent Assoc 2006; 72: 247-248.
17. Fuks AB: Vital pulp therapy with new materials for primary teeth: new directions and treatment perspectives. Pediatr Dent 2008; 30: 211-219.
18. Zarzar PA, Rosenblatt A, Takahashi CS et al.: Formocresol mutagenicity following primary tooth pulp therapy: an *in vivo* study. J Dent 2003; 31: 479-485.
19. Trairatvorakul C, Koothiratrakarn A: Calcium hydroxide partial pulpotomy is an alternative to formocresol pulpotomy based on a 3-year randomized trial. Int J Paediatr Dent 2012; 22: 382-389.
20. Rolling I, Lambjerg-Hansen H: Pulp condition of successfully formocresol-treated primary molars. Scand J Dent Res 1978; 86: 267-272.
21. Ruby JD, Cox CE, Mitchell SC et al.: A randomized study of sodium hypochlorite versus formocresol pulpotomy in primary molar teeth. Int J Paediatr Dent 2013; 23: 145-152.
22. Shabzendedar M, Mazhari F, Alarni M et al.: Sodium hypochlorite vs formocresol as pulpotomy medicaments in primary molars: 1-year follow-up. Paediatr Dent 2013; 35: 329-332.
23. Peng L, Ye L, Guo X et al.: Evaluation of formocresol versus ferric sulphate primary molar pulpotomy: a systematic review and meta-analysis. Int Endod J 2007; 40: 751-757.
24. Liu J. Effects of Nd:YAG laser pulpotomy on human primary molars. J Endod 2006; 32: 404-407.
25. Rood HD, Waterhouse PJ, Fuks AB et al.: Pulp therapy for primary molars. Int J Paediatr Dent 2006; 16: 15-23.

**submitted:**

4.07.2018

**accepted:**

25.07.2018